

*Research Article***Histopathological study on the Indomethacin effect on Gastric Mucosa of Adult Male Albino Rat and the Possible Protective Role of Montelukast****Mohamed A. Desouky, Fatma A. Fouad, Sabreen M. Ahmed and Salma M. Hassan**

Department of Anatomy, El-Minia Faculty of Medicine

Abstract

Background: The effects of anti-ulcerogenic drugs are dependent on the increase in prostaglandin production and reduction in leukotriene production in the gastric mucosa. Montelukast is an anti-asthmatic drug, a selective reversible cysteinyl leukotriene D₂ receptor antagonist. The aim of the present study was to demonstrate the injurious effects of indomethacin on gastric mucosa of adult albino male rat and to evaluate the anti-ulcerogenic effect of montelukast. **Materials and Methods:** Thirty-five adult male albino rats were separated into five groups. Control group, Indomethacin (4 mg/kg), ranitidine (50 mg/kg), montelukast (2 mg/kg) and montelukast (5 mg/kg) were given orally (gavage). Thirty minutes later, indomethacin (4 mg/kg) was administered to all the groups. Six hours later, the animals were sacrificed by decapitation. The ulcer index for each stomach was calculated, and the stomachs were later evaluated histopathologically. **Results:** The present study concluded that indomethacin had a deleterious effects on the structure of the gastric mucosa, administration of montelukast in two dose levels could ameliorate the pathological alterations induced by indomethacin in a dose-related manner, the protection afforded by the highest dose of montelukast (5 mg/kg) was comparable to that of ranitidine.

Keywords: anti-ulcerogenic drugs, prostaglandin, leukotriene

Introduction

Non-steroidal anti-inflammatory drugs (NSAID) comprises of heterogeneous group of medications with analgesic, antipyretic and anti-inflammatory actions. These drugs are widely used to control fever and acute or chronic pain (Litalien et al., 2001). NSAIDs inhibit the two recognized forms of cyclooxygenase enzyme, it causes inhibition of cyclooxygenase-2 which has been more directly implicated in ameliorating inflammation, whereas the inhibition of cyclooxygenase-1 has been related to adverse effects in the gastrointestinal tract (Fitzgerald et al., 2001). Because indomethacin is a non selective inhibitor of cyclooxygenases enzymes, it inhibits the production of prostaglandin of the stomach which maintains the mucous lining of the gastrointestinal tract. Indomethacin, therefore, can produce peptic ulcers which could result in bleeding and/or perforation (Kotani et al., 2005).

Indomethacin induces gastritis through reduction of mucosal blood flow and increase neutrophilic infiltration. Neutrophils appeared to contribute to indomethacin-induced lesions by the production of proteases, elastase and leukotrienes which increased vascular permeability and contributed to cell lysis (Sloan, 1998)

Inflammatory reactions induced by indomethacin are a significant source of reactive oxygen species (ROS). ROS, e.g., H₂O₂ and the superoxide radical, play a causative role in gastric injury (Ganguly et al., 2006).

Ranitidine, one of the H₂ receptor antagonists (H₂RAs), is a potent inhibitor of gastric acid secretion. It is effective in the treatment and prophylaxis of GI lesions aggravated by gastric acid secretion (Brett, 2005).

Montelukast is a new anti-inflammatory drug that interferes directly with leukotriene production and their receptors (Drazen et al., 1999).

Leukotrienes are important mediators of inflammation, vascular injury, ischemia, obstructive pulmonary disease, asthma, and peptic ulcer (Singh et al., 2008 and Freiberg et al., 2009). The leukotrienes (LTs) are lipoxygenase products derived from arachidonic acid (AA) metabolism which are produced by a variety of cells in response to allergic or other cellular stimuli (Samuelsson et al., 1987 and Holgate et al., 1996).

The ulceration induced by indomethacin and NSAIDs is attributed mainly to the inhibition of cytoprotective prostaglandin synthesis resulting in overproduction of LTs and other products of the ω -lipoxygenase pathway (Rainsford, 1998).

Materials and Method

Animal model:

In the current study, 30 adult male albino rats weighing from 200-250 g were used. The animals were maintained on a 12 h/12 h light/dark cycle with ad libitum access to food and water for 1 week before the start of the experiment.

Experimental design:

The animals were grouped into five groups each consisted of 6 rats.

Group A:

The rats were used as control. The rats received a single dose of normal saline.

Group B:

The rats were ingested indomethacin (Indocid; Kahira pharm. & chem. Ind. co. Cairo, Egypt) at a dose of (4 mg/kg bw)

dissolved in normal saline (Arisawa et al., 2006)

Group c:

The rats were ingested ranitidine (Zantac; Glaxosmithkline S.A.E. Elsalam city, Cairo, Egypt) at a dose of (50 mg/kg bw) dissolved in normal saline (Dengiz et al., 2007) and 30 minutes later, indomethacin (4 mg/kg bw) was administered to the rats.

Group D:

The rats were ingested montelukast (Clear air; Amoun pharmaceutical co. El-Obourcity, Cairo, Egypt) at a dose of (5 mg/kg bw) dissolved in normal saline (Dengiz et al., 2007) and 30 minutes later, indomethacin (4 mg/kg bw) was administered to the rats.

Group E:

The rats were ingested montelukast (5 mg/kg bw) dissolved in normal saline (Dengiz et al., 2007) and 30 minutes later, indomethacin (4 mg/kg bw) was administered to the rats.

The drugs were crushed into fine powder and dissolved in normal saline. The drugs were administered by gastric intubation following 12 hours of fasting to assure the full effect of each drug. The gastric tube was left in position for few seconds to prevent regurgitation of the ingested dose.

Macroscopical Examination:

The animals were sacrificed by cervical dislocation six hours after drug ingestion and the stomachs were removed. The stomachs were opened along the greater curvature, rinsed in distilled water and pinned on a wax platform. The gastric mucosae were examined using a magnifying lens to detect gastric ulcers. The severity of the lesion produced by indomethacin was observed and the score was given to the erosion according to the scale of (Till et al., 1988).

Table (1): Rating Scale for erosion:

No lesions	Zero
Petechae	1
Erosion less than 1 mm	2
Erosion from 1:2 mm	3
Erosion from 2:4 mm	4
Erosion more than 4 mm in length	5

The ulcer index was taken to compare the dimensions of the lesion area induced experimentally by indomethacin.

Preparation for paraffin sections:
(Junqueira et al., 1990):

The lesions were excised by sharp blades within a rim of healthy mucosa.

(1) Fixation:

Pieces of tissue were fixed in phosphate buffered saline (PBS, PH 7.2) containing 2.5% formaldehyde for 1 hour (h).

(2) Embedding:

Fixed samples were then washed with water, dehydrated in graded ethanol: 70% ethanol for 1 h, 80% ethanol for two times 1 h each, 90% ethanol for two times 1 h each, 100% ethanol for three times 1 h each. Then cleared in xylene for three times 1 h for the 1st time then 30 minutes twice. Then embedded in wax at 60 C two times for 2hs each. Finally, the samples were embedded in a paraffin wax.

(3) Microtomy:

Microtomy is the means by which tissue can be sectioned to be further processed for microscopic examination. Embedded samples were sectioned at 5µm thickness, using a microtome.

(4) Staining:

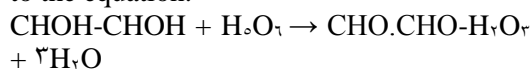
(A) Haematoxylin and Eosin staining
(Luna et al., 1992).

The sections were deparaffinised in two changes of xylene (10 minutes each) then rehydrated in two changes of absolute alcohol (5 minutes each), 95% alcohol for 2 minutes and 70% alcohol for 2 minutes. Then the slides were washed in distilled water and stained in Harris haematoxylin solution for 10 minutes, washed in tap water for 2 minutes, washed in PBS for 2 minutes. Then a counterstain (Eosin Y solution) was added for 1 minute. After that dehydration through 95% alcohol, two changes of absolute alcohol (5 minutes each), clearance in two changes of xylene (5 minutes each) and finally mounting with

xylene based mounting media. The sections were stained with hematoxylin and eosin (H & E) for examination of the architecture of the mucosa.

(B) Periodic Acid Schiff Method
(Bancroft and Gamble, 2002)

The principle of the PAS method depends on the fact that periodic acid forms aldehyde when it splits a chain between two carbon atoms each bearing a hydroxyl group and on colouring the aldehyde with Schiff's reagent, the oxidation takes place according to the equation:



The oxidation of animal tissues that are +ve to staining includes glycogen, mucin, mucoprotein, hyaluronic acid and chitin.

Then sections were dewaxed, hydrated in descending grades of alcohol then in distilled water, Oxidized in 1% of periodic acid for 5 minutes, Washed well with several changes of distilled water, treated with Schiff's reagent for 15 minutes, Washed in running tap water for 5-10 minutes, Counter stained in Harris haematoxylin for 5 minutes and differentiated in 1% acid-alcohol, washed well in tap water and dehydrated in ascending grades of absolute alcohol. Finally, cleared in xylene and mounted in Canada balsam.

The sections were stained with periodic acid Schiff (PAS) for studying the changes in the mucus secretion. Glycogen and other reactive carbohydrates appeared magenta. Nuclei appeared blue.

Image capture

Tissue sections were examined and images were digitally captured using a hardware consisting of a high-resolution color digital

camera mounted on an Olympus microscope (Olympus, Japan), connected to a computer, and then analyzed using Adobe Photoshop.

Statistical analysis

Data analysis was achieved with Statistical Package for Social Sciences (SPSS) version 20. Means and standard deviations were used to describe the numerical variables. A P value less than 0.05 was accepted as significant. Groups of data were compared with an analysis of variance (ANOVA).

Results

A- Gross Morphological Study:

Group A: (Control)

Examination of this group using magnifying lens revealed normal longitudinal gastric mucosal folds. (Fig. 1).

Group B: (received indomethacin only)

Gross examination of different rats of the group B manifested variable lesions of different severity and extent. There was many ulcers of different dimensions. (Fig. 2).

Group C: (received indomethacin and ranitidine)

The mucosa of the body region displayed fewer and further smaller ulcers as compared to group B and C surrounded by apparently normal mucosa. (Fig. 3).

Group D: (received indomethacin and montelukast 0.5 mg/kg)

The mucosa of the body region showed fewer ulcers of smaller dimensions as compared to group B (Fig. 4).

Group E: (received indomethacin and montelukast 1 mg/kg)

The mucosa of the stomach illustrated fewer and smaller ulcers as compared to group B surrounded by apparently normal mucosa. (Fig. 5).

B- Histological Results:

Group A: (Control):

In the control group, the hematoxylin and eosin stained sections showed the body wall of the stomach which is formed of four layers: mucosa, submucosa, muscularis and serosa. The mucosa is formed of surface epithelium, lamina propria of C.T. which contains gastric glands and the muscularis mucosa. Each gland contains different types of cells; the surface epithelial cells, parietal or oxyntic cells and the peptic or the chief

cells. (Fig. 6). In PAS stained sections of control group, the surface mucus cells and their mucous secretion showed positive PAS reaction. (Fig. 7).

Group B: (received indomethacin only):

In hematoxylin and eosin stained sections the gastric mucosa of this group displayed marked damage in the form of noticeable erosions with ulcerations, exfoliated epithelium. The gastric glands exhibited dilatation and disturbance in architecture (Fig. 8). In PAS stained sections, the mucus layer lining the gastric epithelium exhibited a weak PAS reaction (Fig. 9).

Group C: (received indomethacin and ranitidine)

In hematoxylin and eosin stained sections the gastric mucosal epithelial lining and the glandular architecture of this group was nearly normal. However some slides showed slight dilatation of the gastric glands. The submucosa appeared almost normal but few dilated and congested blood vessels were detected (Fig. 10). In PAS stained sections the mucus layer at the surface clarified positive PAS reaction (Fig. 11).

Group D: (received indomethacin and montelukast 0.5 mg/kg)

In hematoxylin and eosin stained sections the gastric mucosal epithelial lining and the glandular architecture of this group was nearly normal however some slides showed limited areas of gastric erosions and slight dilatation of the gastric glands

Submucosa showed dilated, congested blood vessels, oedema and inflammatory cell infiltration (Fig. 12). In PAS stained sections the mucus layer at the surface clarified positive PAS reaction. (Fig. 13).

Group E: (received indomethacin and montelukast 1 mg/kg)

In hematoxylin and eosin stained sections the gastric mucosal epithelial lining and the glandular architecture of this group was nearly normal. However some slides showed slight dilatation of the gastric glands. Submucosa showed dilated, congested blood vessels in some slides and there was significant decrease in the inflammatory cell infiltration. (Fig. 14).

In PAS stained sections the mucus layer at the surface clarified positive PAS reaction (Fig. 15).

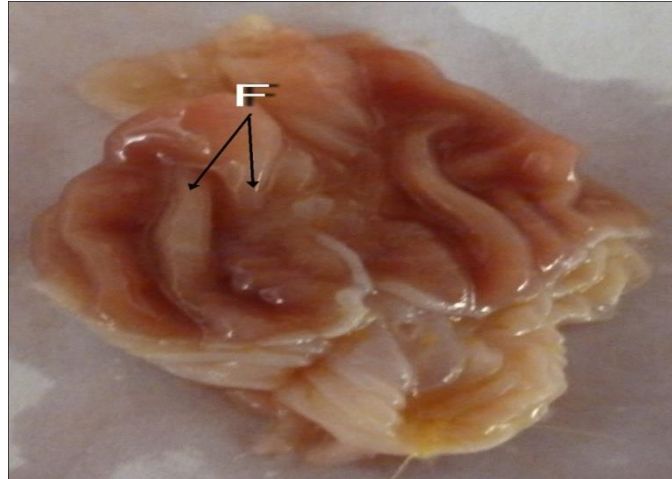


Fig. (1): Photograph of gastric mucosa of group (A) showing normal longitudinal mucosal folds (F).

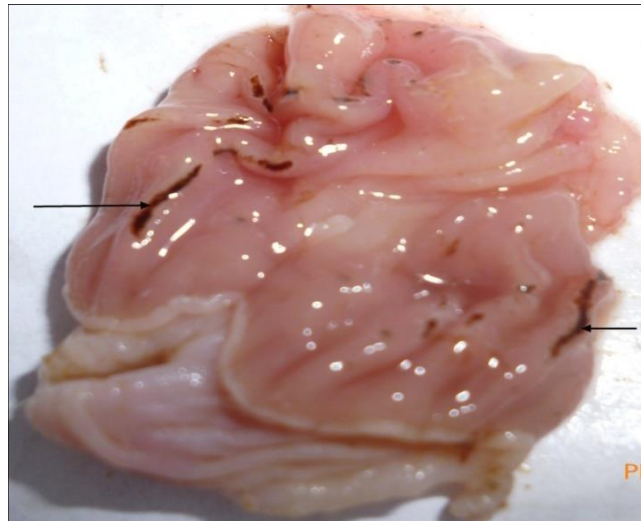


Fig. (2): Macrograph of group (B) showing multiple ulcers of variable size and diffuse congestion of gastric mucosa (arrows).

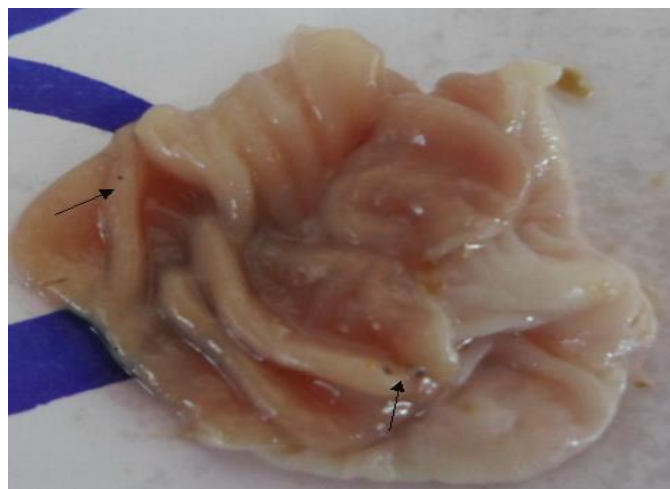


Fig. (3): Photograph of gastric mucosa of (C) demonstrating very small ulcer with surrounding nearly normal gastric mucosa (arrows).

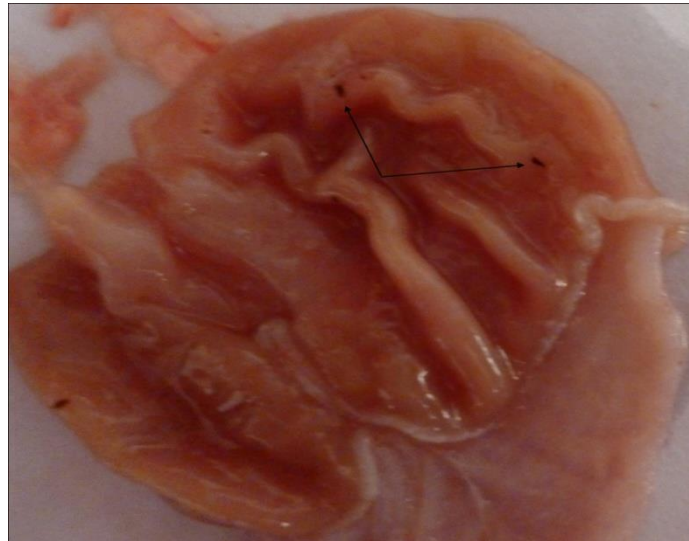


Fig. (4): Photograph of gastric mucosa of group (D) demonstrating small ulcers with surrounding nearly normal gastric mucosa(arrows)

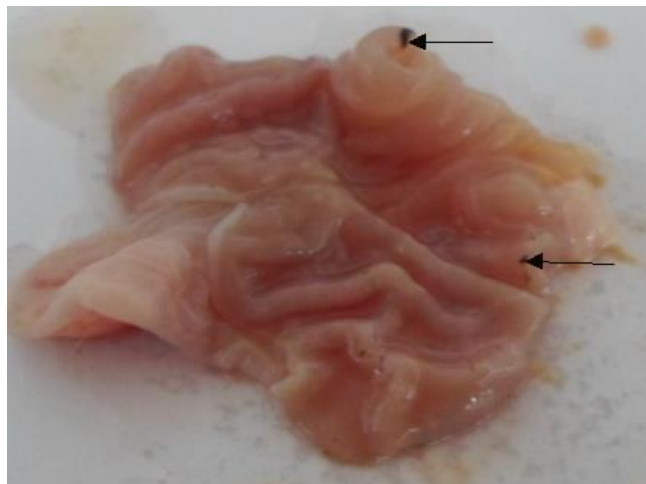


Fig. (5): Photograph of gastric mucosa of group (E) demonstrating very small ulcers with surrounding nearly normal gastric mucosa (arrows).

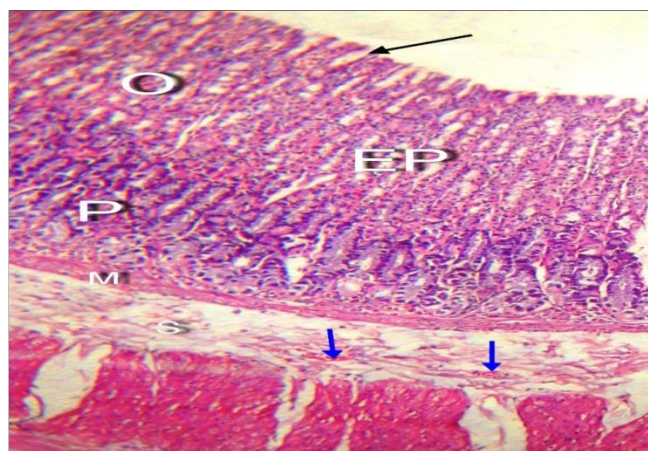


Fig.(6): A photomicrograph of a section of rat stomach of group(A) (normal control) displaying epithelial layer (EP) limited by muscularis mucosae (M) , gastric pits (arrow heads) and acidophilic oxyntic cells (O) and basophilic peptic cells (P). The submucosa (S) contains blood vessels (arrow heads). (H&E.X200)

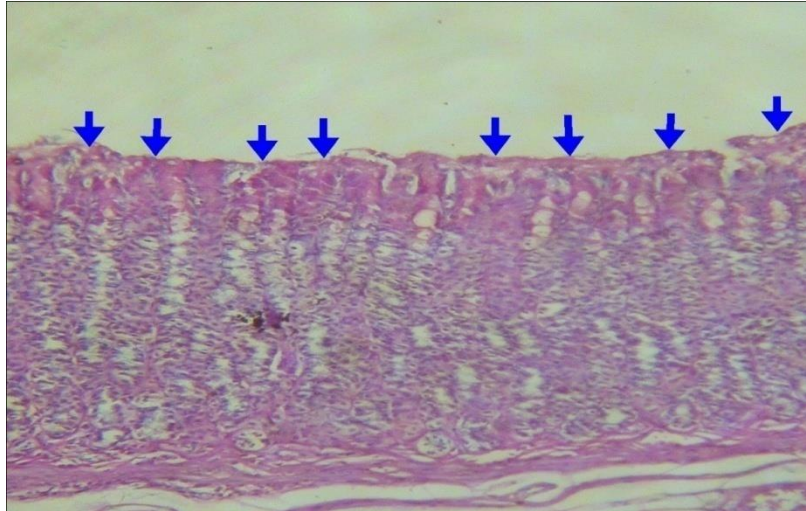


Fig. (v): A photomicrograph of a section of rat gastric mucosa of group (A) exhibiting positive PAS reaction at the surface (arrows). (PAS.X200)

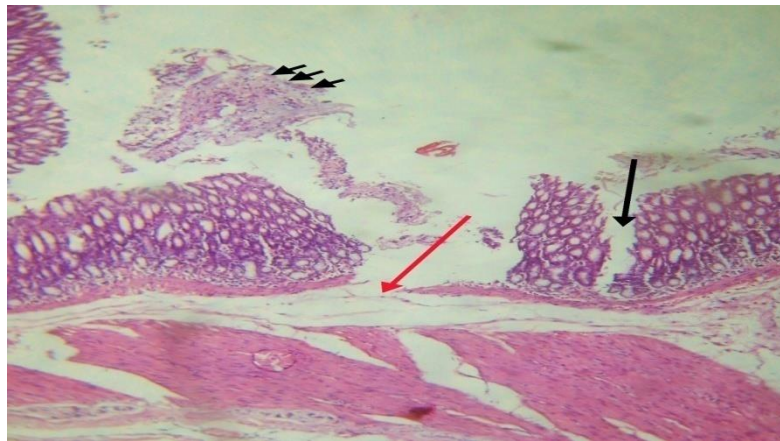


Fig. (w): A photomicrograph of a section of rat gastric mucosa of group (B) displaying ulcer (Red arrow) with cellular exfoliation (arrow heads) and erosions in the mucosa (black arrow) with oedema in the submucosa. There is rupture of the muscularis mucosa denoting ulcer formation and observable dilatation of the gastric glands. (H&E.X200)

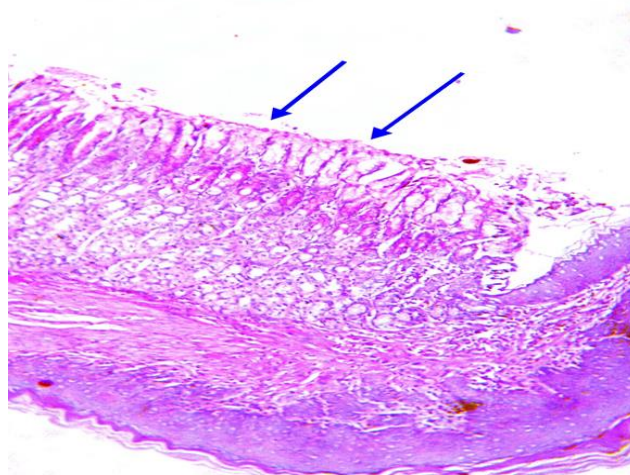


Fig. (z): Micrograph of subgroup (B) displaying weak PAS reaction at the surface of the mucosa at the region of the gastroesophageal junction. (PAS.X200)

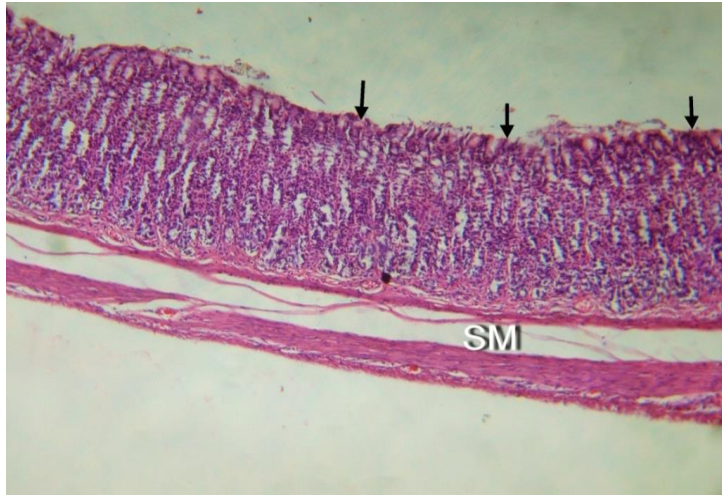


Fig. (10): A photomicrograph of a section of rat gastric mucosa of group (C) showing normal architecture of gastric mucosa. The submucosa is almost normal (SM). (H&E.X200)

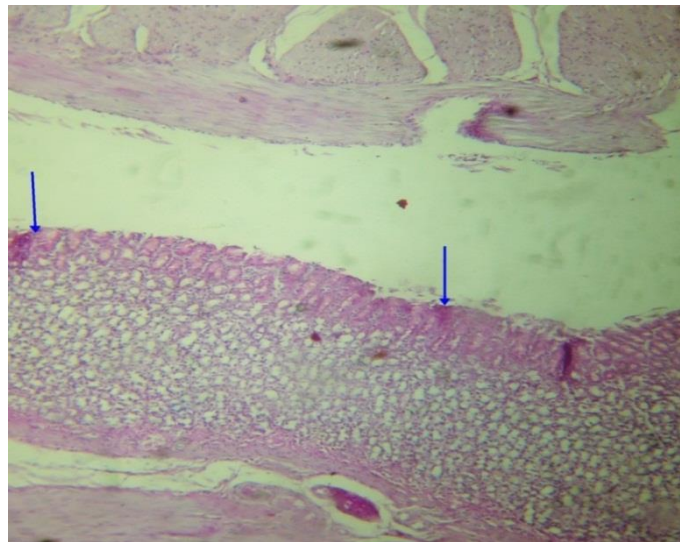


Fig. (11): A photomicrograph of a section of rat gastric mucosa of group (C) exhibiting positive PAS reaction at the surface (arrows). (PAS.X200)

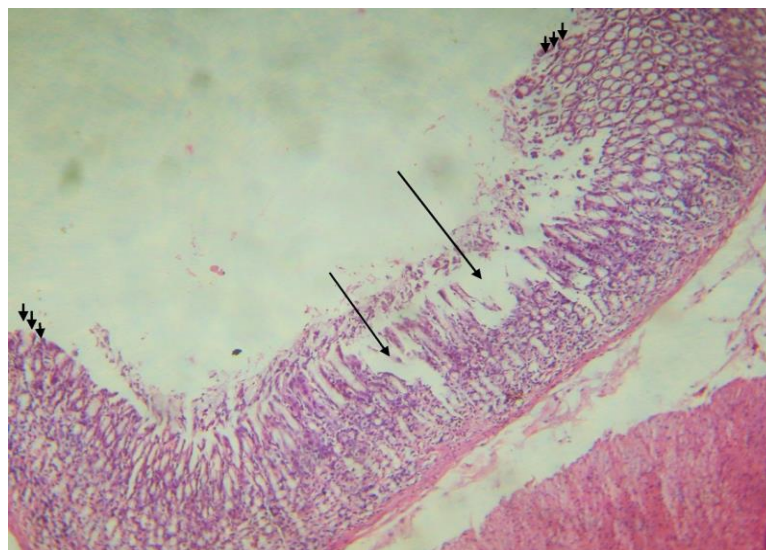


Fig. (12): A photomicrograph of a section of rat gastric mucosa of group (D) showing gastric erosions (long arrows) though normal architecture of gastric gland is preserved (arrow heads). (H&E.X200)

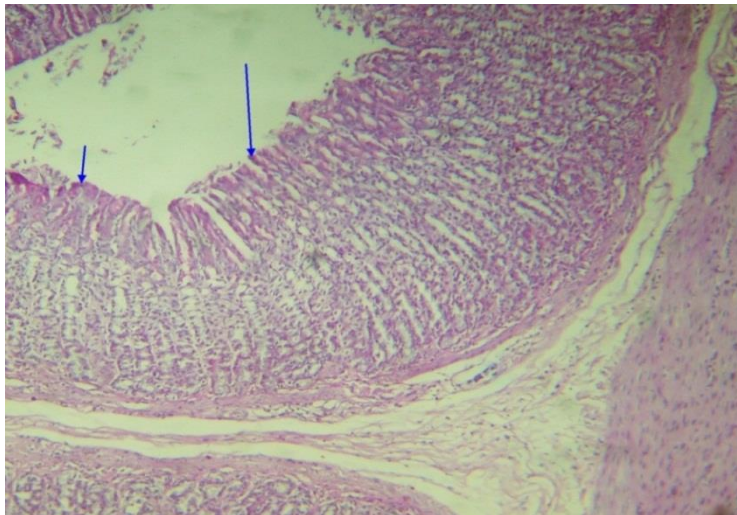


Fig. (13): Micrograph of subgroup (D) showing positive PAS reaction of the surface mucus cell layer. (PAS.X200)

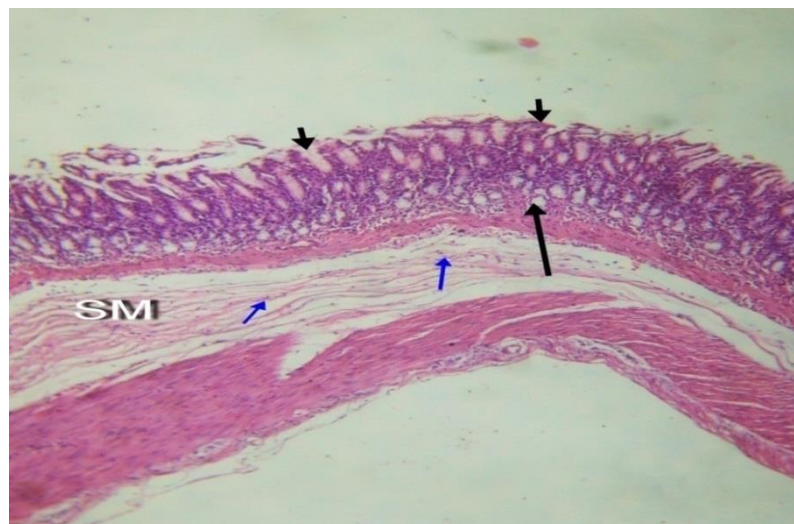


Fig. (14): A photomicrograph of a section of rat gastric mucosa of group (E) detecting almost normal epithelial lining of gastric mucosa (arrow heads), slightly dilated glands (long arrows), oedema and inflammatory cells infiltration (blue arrow) in the submucosa (SM). (H&E.X200)

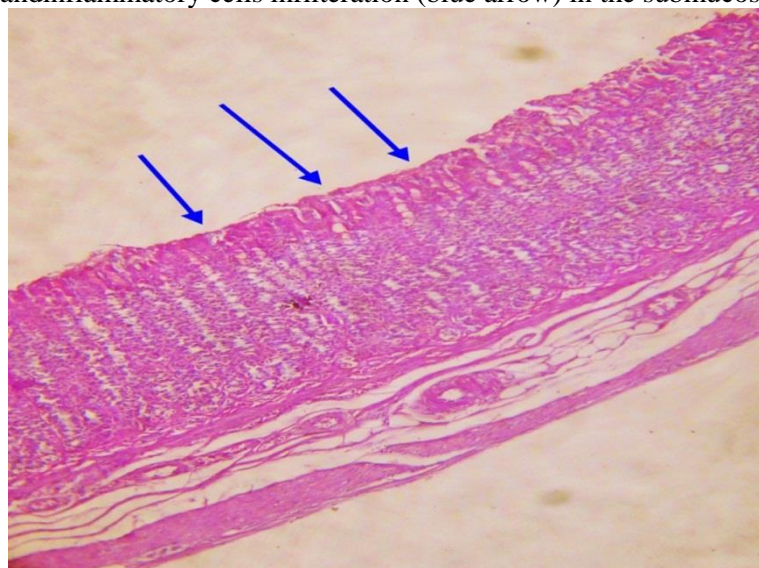


Fig. (15): A photomicrograph of a section of rat gastric mucosa of group E exhibiting positive PAS reaction at the surface (arrows). (PAS.X200)

Table (2): Showing a comparison between the statistical data of the ulcer indices of different groups.

Ulcer index	Number	Range	Mean±SD	p-value
Group B (Indomethacin group)	7	23-70	40.9±16.6	0.001*
Group C (Indomethacin + ranitidine)	7	0-19	0.4±6.6	
Group D (Indomethacin+montelukast 0mg)	7	4-20	12.4±6.3	
Group E (Indomethacin+ montelukast 2 mg)	7	0-9	0.1±3.7	
Total	30	0-70	17.2±19.4	

*p-value is significant it less than 0.05 ANOVA test.

Data presented in Table 2 show that oral administration of indomethacin (4 mg/kg) induced ulcerative lesions that achieved an ulcer index (U.I.) of 40.9±16.6. Administration of ranitidine (2 mg/kg.) in group (C), 30 minutes before indomethacin administration significantly ($p < 0.01$) protected the stomach from gastric lesions induced by indomethacin and achieved an U.I. of 0.4±6.6 as compared to indomethacin-treated group.

On the other hand, administration of montelukast at its dose levels (0 and 2 mg/kg.) in both groups (D) and (E) 30 minutes before indomethacin administration significantly dose-dependently ($p < 0.01$) reduced the U.I., as compared to indomethacin-treated subgroup, to 12.4±6.3 and 0.1±3.7, respectively.

Discussion

In the control group (group A), Examination of this group using magnifying lens revealed normal longitudinal gastric mucosal folds, similar observations of this result was reported by (Sinha et al., 2010).

In hematoxylin and eosin stained sections of (group A) showed that the body wall of the stomach is formed of four layers: mucosa, submucosa, muscularis and serosa. The mucosa is formed of surface epithelium, lamina propria of C.T. which contains gastric glands and the muscularis-mucosa. The gastric submucosa is formed of loose areolar C.T. containing blood

vessels, same findings were reported by (Liu et al., 2010).

In PAS stained sections of (group A), the surface mucus cells and their mucous secretion showed positive PAS reaction, this finding was identical with (Dhiyaaldeen et al., 2014) who noted that, the magenta colour in the apical cells which reflected the glycogen accumulation in the gastric gland. In the present work, on studying the effect of indomethacin on the mucosa of the stomach in group (B), it was found that it induced observable high ulcer index, this finding was agreed with (Dengiz et al., 2007), who reported high ulcer index in indomethacin group.

The present study showed that in group B, by gross examination, there were ulcers of different dimensions and the mucosa showed congestion, this was in line with (Liu et al., 2010).

In the present study the microscopic examination of group (B), revealed marked damage in the gastric mucosa in the form of noticeable erosions with ulceration, exfoliated epithelium. Similar observation reported by (Liu et al., 2010) who observed the serious damaging effect of indomethacin on gastric epithelium. Indomethacin was seemed to cause ulcer mainly through suppression of PGE₂ synthesis (Motilva et al., 2000).

In the current study, there was dilated, congested blood vessels and areas of

haemorrhage (which appeared black) were noticed. Similar finding was reported by (sinha et al., 2010). (Suleyman et al., 2009) stated that NSAIDs such as indomethacin, disturbs the oxidative balance in gastric tissue and initiates lipid peroxidation which causes gastric damage by producing reactive oxygen species (ROS). (La Casa et al., 2000) reported that attraction and subsequent involvement of inflammatory cells to the specific tissue site are a hallmark incident in the initiation of pathogenesis of gastric mucosa.

Activated neutrophils can induce injury physically by occluding micro-vessels and via the production of many pro-inflammatory and pro-oxidative enzymes, for instance, myeloperoxidase (MPO) enzyme or through production of superoxide and other reactive oxidants (Chatterjee et al., 2007).

The decreased mucous secretion as proved in the current study by weak PAS reaction, was recorded also by (Dhiyaaldeen et al., 2014) who postulated that this change was closely related to inhibition of prostaglandin synthesis. In the present study, in group (C) which received ranitidine and indomethacin, ranitidine caused reduction of the ulcer index when compared with group (B) that received indomethacin alone. This finding was in agreement with (Patil et al., 2012) who observed that ranitidine significantly decreased ulcer index in indomethacin and pylorus ligation induced ulcers model in rat.

In the present work, on gross examination of group (C), the gastric mucosa revealed fewer and smaller ulcers surrounded by apparently normal mucosa. Identical observation by (Du et al., 2013) who observed that ranitidine attenuated mucosal damage against alcohol induced ulceration in rat. (Shah et al., 2003) attributed the gastroprotective effect of ranitidine to its antagonism on the stimulatory effect of histamine on gastric secretion.

In the same group (C), histological examination, the hematoxylin and eosin stained sections showed gastric mucosal

epithelial lining and the glandular architecture of this group was nearly normal. These observations were identical to the results reported by (Moustafa et al., 2013). In the current study, the PAS stained sections of group (C) clarified positive reaction, this result was in line with (Moustafa et al., 2013) who reported that Pretreatment with ranitidine significantly restored tissue mucin concentration in the gastric mucosa as compared to indomethacin group.

However, there is an evidence that COX inhibition by NSAIDs diverting arachidonic acid metabolism to ω -lipoxygenase (ω -LOX) pathway, suggests the possible role of leukotrienes (LTs) in vascular changes and mucosal damage associated with the use of NSAIDs (Takeuchi et al., 2000).

In the present study, in (group D) receiving the indomethacin, and motelukast (20 mg/kg) and in (group E) receiving indomethacin, and motelukast (40 mg/kg), there was partial protection of the gastric mucosa manifested by high significant reduction of the ulcer index as compared to the group (B) receiving indomethacin alone.

These findings were identical with (Muthuraman et al., 2010) who studied the effects of 20 , 40 , and 80 mg/kg doses of montelukast on the ulcer index in pyloric ligation (PL) and water immersion stress (WIS) induced peptic ulcer models. The results have indicated that montelukast produced significant reduction in ulcer index as compared with the diseased group. These effects were observed in a dose dependent manner, and administration of high doses of montelukast produced significant reduction in ulcer index.

In the present study, macroscopic examination of group (D) and group (E) displayed obvious improvements as the mucosa of the stomach illustrated fewer and smaller ulcers surrounded by apparently normal mucosa. Similar observations recorded by (Dengize et al., 2007) who determined macroscopically the gastro protective effect of 20 , 40 , and 80 mg/kg

doses of montelukast on indomethacin-induced gastric damage in rats.

In the present study, group (D) and group (E), in hematoxylin and eosin stained sections the gastric mucosal epithelial lining and the glandular architecture of the stomach were nearly normal.

Similar findings reported by (sener et al., 2005) who investigated the effects of montelukast on alendronate sodium (ALD) induced tissue damage in rat stomach, they noticed that in the ALD and montelukast treated group, degeneration and dilatation of gastric glands were reduced, and in some areas the appearance of the glands was almost similar to the control group.

Montelukast is a well known cysteinyl leukotriene receptor antagonist and leukotrienes when liberated in stomach causes paracrine cell damage, which in turn leads to more acid secretion (Haeggstrom et al., 2002). Hence this acid secretion is supposed to be blocked by montelukast due to its LT antagonist action (Muthuraman et al., 2010).

Neutrophils are a potential source of oxygen free radicals and are considered to be a major effector cell in the tissue damage occurring in several inflammatory diseases (Sullivan et al., 2000). Activated neutrophils are known to cause tissue injury through the production and release of reactive oxygen metabolites and cytotoxic proteins (e.g. proteases, myeloperoxidase, lactoferrin) into the extracellular fluid (Reiter et al., 2000).

Al-Bayati et al., 2010 aimed at investigating the effect of montelukast on some oxidant and antioxidant parameters in stomach tissue of rabbits with gastric ulcer and its role in gastroprotection, they concluded that the gastroprotective effect of montelukast can be attributed to its ability to balance oxidant - antioxidant status.

In the present study, there was an improvement in the mucus layer in group(D) and group(E) as illustrated by the positive PAS reaction. It was reported by (Dengiz et al., 2013) that the

gastroprotective effects of montelukast may be due to its possible local increase in the synthesis of cytoprotective prostaglandin as the prostaglandin play important role in the synthesis of cytoprotective gastric mucous.

References

1. Al-Bayati, N.J.; Ewadh, M.J. and Ijam, A.H. (2010): Gastroprotective and Antioxidant Potential of Montelukast against Acetyl Salicylic Acid Induced Gastric Ulcer Model in Male Rabbits. *Int. J. Curr. Microbiol. App.Sci.*, 2(2): 80-89.
2. Arisawa, T.; Shibata, T. and Nagosaka, M. (2006): Is omeprazole or misoprostol superior for improving indomethacin-induced delayed maturation of granulation tissue in rat gastric ulcers? *Digestion.*, 77: 32-39.
3. Bancroft, D. and Gamble, M. (2002): *theory and practice of histological techniques* (fifth edition); chap. 5: 157-158. publ. London, New York, Philadelphia.
4. Brett, S. (2005): The use of proton pump inhibitors for gastric acid suppression in critical illness. *Crit. Care.*, 9: 40-50.
5. Chatterjee, M.; Saluja, R.; Kanneganti, S.; Chinta, S. and Dikshit, M. (2007): Biochemical and molecular evaluation of neutrophil NOS in spontaneously hypertensive rats, *Cell.Mol. Biol. (Noisy-le-grand).*, 53: 84-93.
6. Dengiz, G.O.; Odabasoglu, F.; Halici, Z.; Cadirci, E. and Suleyman, H. (2007): Gastroprotective and antioxidant effects of montelukast on indomethacin-induced gastric ulcer in rats, *J. Pharmacol. Sci.*, 109: 94-102.
7. Dengiz, O.G.; Cadirci, E. and Yurdakan, G. (2013): Histopathologic evaluation of anti-ulcerogenic effect of montelukast in indomethacin-induced experimental ulcer model. *Turk. J. Gastroenterol.*, 24(2): 88-92.
8. Drazen, J.M. ; Israel, E. and O'Byrne, P.M. (1999): Treatment of asthma with drugs modifying the leukotriene pathway, *New Engl. J. Med.*, 341: 197-206.
9. Dhiyaaldeen, S.M.; Amin, Z.A.; Darvish, P.H; Mustafa, I.F.; Jamil, M.

- M. et al., (2014): Protective effects of (1-(α -hydroxy-phenyl)- β -methyl-propenone chalcone in indomethacin induced gastric erosive damage in rats BMC Veterinary Research., 10(1):961
10. Du, Y.; Zhao, W.; Lu, L.; Zheng, J.; and Hu, X.; et al., (2013): Study on the antiulcer effects of Veronicastrum axillare on gastric ulcer in rats induced by ethanol based on tumor necrosis factor- α (TNF- α) and endothelin-1 (ET-1). Asian Pac. J. Trop. Biomed., 3(12): 920-924.
11. Freiberg, J. J.; Dahl, M.; Hansen, A. T.; Grande, P. and Nordestgaard, B. G. (2009): Leukotriene C (4) synthase and ischemic cardiovascular disease and obstructive pulmonary disease in 13,000 individuals, J.Mol.Cell.Cardiol., 46:579-586.
12. Fitzgerald, G.A. and Patron, C. (2001): The selective inhibitors of cyclooxygenase-2. N. Engl. Med., 345: 433-434.
13. Ganguly, K.; Kundu, P. and Swarnakar, S. (2006): Hydrogen peroxide-mediated downregulation of matrix metalloproteinase-2 in indomethacin-induced acute gastric ulceration is blocked by melatonin and other antioxidants. Free Radical Biol. Med., 41: 911-920.
14. Haeggstrom, J.Z. and Wetterholm, A. (2002): Enzymes and receptors in the leukotriene cascade, Cell. Mol. Life Sci., 59: 742-753.
15. Holgate, S.T.; Bradding, P. and Sampson, A.P. (1996): Leukotriene antagonists and synthesis inhibitors: new directions in asthma therapy. J. Allergy Clin. Immunol., 98: 1-13.
16. Janqueira, L.C.; Carneiro, J. and Kelly, R.O. (1990): Basic histology 8th ed. Lebanon; Librairie du Liban., 281: 288.
17. Kotani, T; Kobata, A. and Nakamura, E. (2000): Roles of cyclooxygenase-2 and prostacyclin/ IP receptors in mucosal defense against ischemia/reperfusion injury in mouse stomach. J. Pharmacol. Ther., 316: 547-550.
18. La Casa, C.; Villegas, I.; De la Lastra, A.C.; Motilva, V. and Calero, M. M. J. (2000): Evidence for protective and antioxidant properties of rutin, a natural flavone, against ethanol induced gastric lesions. J. Ethnopharmacol., 71: 40-53.
19. Litalien, C. and Jacqz-Aigrain, E. (2001): Risks and benefits of nonsteroidal anti-inflammatory drugs in children: a comparison with paracetamol. Paediatr. Drugs., 3: 817-88.
20. Liu, Y.; Zhang, Z.; Zheng, Y.; Chen, H.; Yu, X., et al., (2010): Gastroprotective effect of andrographolide sodium bisulfite against indomethacin-induced gastric ulceration in rats. International Immunopharmacology., 26: 284-291.
21. Luna, L. (1992): Methods for Staining Cellular Entities. American Histolabs., 4: 71: 92.
22. Muthuraman, A. N. and Sood, S. (2010): Antisecretory, antioxidative and antiapoptotic effects of montelukast on pyloric ligation and water immersion stress induced peptic ulcer in rat. Prostaglandins, Leukotrienes and Essential Fatty Acids., 83: 50-60.
23. Motilva, V.; Alarcon de la Lastra, C.; Bruseghini, I. Manuel Herrerias, J. and Sanchez- Fidalgo, S. (2000): COX expression and PGE(2) and PGD(2) production in experimental acute and chronic gastric lesions, Int. Immuno-pharmacol., 5: 379-379.
24. Moustafa, Y. M.; Khoder, D. M; EL-Awady, E. E. and Zaitone. S. A. (2013): Sildenafil citrate protects against gastric mucosal damage
25. Patil, A. N.; Advani, M. G. Mali, S. N. Pawar, S. and Raut, S. B. (2012): Evaluation of anti-ulcer effect of amlodipine in gastric ulcer models in rats. Indian J. Pharmacol., 44(3): 387-389.
26. Rainsford, K. D. (1987): Gastric ulcerogenicity of non-steroidal anti-inflammatory drugs in mice with mucosa sensitized by cholinomimetic treatment. J. Pharm. Pharmacol., 39: 779-782.
27. Reiter, R.J.; Tan, D.X.; Osuna, C. and Gitto, E. (2000): Actions of melatonin in the reduction of oxidative stress: a review, J. Biomed. Sci., 7: 444-458.
28. Samuelsson, B.; Dahlen, S.E.; Lindgren, J.A.; Rouzer, C.A. and

- Serhan, C.N. (1987): Leukotrienes and lipoxins: structures, biosynthesis, and biological effects. *Science*, 237:1151-1156.
29. Sener, G.; Kapucu, C.; Cetinel, S.; et al. (2008): Gastroprotective effect of leukotriene receptor blocker montelukast in alendronate-induced lesions of the rat gastric mucosa. *Prostaglandins Leukot Essent Fatty Acids*, 92: 1-11.
30. Shah, P.J.; Gandhi, M.S.; Shah, M.B.; Goswami, S.S. and Santani, D. (2003): Study of *Mimusops elengi* bark in experimental gastric ulcers. *J Ethnopharmacol*; 89: 308-311.
31. Singh, S.; Khajuria, A. and Taneja, S.C. et al., (2008): The gastric ulcer protective effect of boswellic acids, a leukotriene inhibitor from *Boswellia serrata*, in rats. *Phytomedicine*, 15: 818-820.
32. Sinha, K.; Sadhukhan, P.; Saha, S.; Pal, B.P. and Sil, P.C. (2010): Morin protects gastric mucosa from nonsteroidal anti-inflammatory drug, indomethacin induced inflammatory damage and apoptosis by modulating NF- κ B pathway. *Biochimica et Biophysica Acta*, 1800: 769-783.
33. Sloan, J.M. (1998): Protective effect of famotidine, omeprazole and melatonin against non steroidal anti-inflammatory drugs. *Am. J. Pathol.*, 153: 833-844.
34. Suleyman, H.; Cadirci, E.; Albayrak, A.; Polat, B. Halici, Z.; Koc, F. et al., (2009): Comparative study on the gastroprotective potential of some antidepressants in indomethacin induced ulcer in rats, *Chem. Biol. Interact.*, 180: 318-324.
35. Sullivan, G.W.; Sarembock, I.J. and Linden, J. (2000): The role of inflammation in vascular diseases, *J. Leukoc. Biol.*, 67: 591-602.
36. Takeuchi, K.; Tanaka, A.; Hayashi, Y. and Yokota, A. (2000): COX inhibition and NSAID-induced gastric damage-roles in various pathogenic events. *Curr Top Med Chem* ., 0(0): 470-486.
37. Till, M.; Gati, T.; Rabai, K.; Szombath, D. and Szekely, J.I. (1988): Effect of [D-Met⁵, Pro⁶] enkephalinamide on gastric ulceration and transmural potential difference. *Eur J Pharmacol.*, 150: 320-330.